

OCCURRENCE OF CONGENITAL TROPICAL THEILERIOSIS ASSOCIATED WITH OXIDATIVE STRESS AND ANTIOXIDANT RESPONSE IN CROSSBREED NEW BORN CALVES IN NEW VALLEY GOVERNORATE. EGYPT.

Osman F.A^{1*}, Gaadec. H. I. M²

^{*1}Head researcher, Parasitological unite, Animal Health research Institute, New-Valley branch.

²First researcher, Biochemistry unite, Animal Health Research Institute .Assuit branch.

***Corresponding Author:-**

Abstract:-

In this study the occurrence of intrauterine transmission pathway of theileria spp from infected cows to its offspring was evaluated and the oxidative stress of theileria infection on new born calves and its body reaction by antioxidant response was determined. Twenty pregnant cows at the last trimester stage of pregnancy and its offspring from some localities in New-Valley Governorate and suffering from theileriosis(different degree of parasitemia) by clinically and laboratory (blood smears and PCR test) examine .Examination of 18 living new born calves where the rest number of newborn calves(two calves) dead during parturition, revealed 7(38.88%) calves only were positive by direct smear and indicated massive parasitemia but by PCR test revealed 14 out of 18(77.77%) new born calves were positive. The mean value of hematological parameters indicated significant decrease in TRBCs count, HB content, PCV (%), MCV (fl), MCH (p g/dl) and MCHC (g/dl) and significant increase in TWBCs count in comparison to control healthy calves, while evaluation of oxidative stress which revealed significantly increased in both parameters (MDA and PCs) by (P < 0.001), and no significant change in catalase enzyme and significant decrease in glutathione enzyme in comparison to healthy control group. Thereby from the results we can see the neonate calf acquired theileria annulata infection from her infected and/or immune carrier mother during gestation period and affected newborn calves develop clinical signs either soon after birth or during neonate life, lipid peroxidation is one of the important consequences of oxidative stress.

Keyword:- Congenital theileriosis, newborn calves, oxidative stress.

INTRODUCTION;

Theileriosis is one of the most economically devastating diseases of livestock in Egypt, where an estimate stated that bovine tropical theileriosis costs the Egyptians livestock sector about several million annually through the cost of treatment and animal mortality.

Theileria Spp is a tick borne protozoan parasite of cattle that multiplies in erythrocytes, causing mild hyperthermia and anemia, infected calves show severe clinical signs associated with high morbidity but low mortality especially when exposed for any other stress as infected with other parasites or virus. Bovine tropical theileriosis (BTT) has been a persistently recognized major constraint to livestock improvement programmers where in enzootic areas, the disease accounts for high mortality up to 70% in dairy cattle especially calves and over 200 million animals are at risk ^[1, 2]. Theileriosis is a tick-borne trans-staidly transmitted disease caused by *Theileria Spp*, involving *Hyalomma spp* as vector in the subcontinent where the host gets infected 2–4 days after next developmental of *Hyalomma spp* start feeding blood and higher mortality in susceptible host is often encountered.

Theileria annulata, is the causative agent of lymph proliferative disease of cattle (Bovine tropical theileriosis), that cause significant economic losses in large parts of Asia and Africa where the parasite acts as a serious constraint to cattle production in endemic areas causing lethal infections in exotic cattle and considerable mortality in indigenous and crossbred stock ^[3, 4], but ^[5] said that the bovine mortality rate rises up to 40-60% and even more.

Theileria genus differentiates themselves from the *Babesia parasites* by having a schizont stage in their life cycle which parasitized the host's white blood cells, like other parasites (such as *Toxoplasma spp* and *Plasmodium spp.*), the life cycle of Theileria is complex and involves several morphologically different stages where sporozoite entry in target cells is a rapid process and within 15-30 minutes of invasion the infective sporozoite eliminates the enclosing host cell membrane and free in cytoplasm then differentiates into a multinucleated syncytium called a schizont^[6, 7].

Approximately 15 species of *Hyalomma* have been shown to transmit *T. annulata* either naturally or experimentally and the status of several other species is still in doubt where most of these ticks undergo a 2- or 3-host cycle on vertebrate hosts either engorging as larvae and nymphs on the first host before attaching to a second for the adult feed or utilizing a fresh host for each of the 3 blood-meals, normally ticks are infected when feeding as larvae or nymphs and transmit the parasite in the following instar (trans-staidly transmission). However, it has been suggested that transmission of the parasite from the adult female tick to the eggs (trans-ovarian transmission) may occur ^[8]. Also rare cases of-suspected intrauterine infection of calves have been recorded including cases diagnosed in aborted calf fetuses, in 2- to 4- day old calves and in a 7-day old calf ^[9], also ^[10], said that " Red cell bodies" of *Thieleria. annulata* have been reported as being seen in a newborn calf and in fetal tissues associated with neonatal death and abortion. In addition to that ^[11], stated that trans-placental Bovine Tropical Theileriosis (BTT) causing a fatal disease in a 3 day old neonate cross bred calf and cerebral form of the disease (turning sickness) in a cow were incriminated to *T. annulata* infection and documented elsewhere.

Clinical manifestations of tropical theileriosis in newborn calves diverge from per acute to acute or sub-acute to chronic. It mainly depends upon the damaging effect of pathogen on lymphoid tissues and susceptibility of host. A marked rise in body temperature, reaching 40-42°C, is followed by lethargy, lacrimation, nasal discharge, exophthalmia and swelling of superficial lymph nodes; hemolytic anemia is the characteristic features of tropical theileriosis ^[12, 13].

Oxidative stress reflects an imbalance between the systemic manifestation of reactive oxygen species and a biological system's ability to readily detoxify the reactive intermediates or to repair the resulting damage where disturbances in the normal redox state of cells can cause toxic effects through the production of peroxides and free radicals that damage all components of the cell, including proteins, lipids, and DNA. Oxidative stress from oxidative metabolism causes base damage, as well as strand breaks in DNA. Base damage is mostly indirect and caused by reactive oxygen species (ROS) generated, e.g. O₂⁻ (superoxide radical), OH (hydroxyl radical) and H₂O₂ (hydrogen peroxide).^[14] Further, some reactive oxidative species act as cellular messengers in redox signaling. Thus, oxidative stress can cause disruptions in normal mechanisms of cellular signaling. *Theileria. annulata* infection in cattle induces high levels of pro-inflammatory cytokines such as interleukin-1 (IL-1) and ILII, tumor necrosis factor and interferon as activators of natural killer cells ^[15]. These cytokines cannot be controlled by the host immune system and play a major contributory role in the pathology of the disease and lead ultimately to death in acute cases of the infection^[16]. Triggering of this pro-inflammatory cascade can stimulate the circulating phagocytes to generate excessive amount of the reactive oxidants, free radicals such as nitric oxide radical (NO₂) in addition to hydrogen peroxide (H₂O₂) to act as a host defense against the invading parasite^[17]. Within the erythrocyte, the parasites depend on hemoglobin (HB) as their primary nutrient and accumulate vast amounts of iron from heme which act as a catalyst in the formation of superoxide anion radical (O₂⁻), hydro peroxide radical (OH) and H₂O₂ ^[18]. Further, neonatal erythrocyte which is more prone to release iron generates greater amounts of O₂⁻ and OH than adult erythrocyte ^[19, 20]. When free radicals are generated at high levels, they act as cytotoxic agents and can result in biomolecular oxidative damage to lipids and proteins which contribute to pathological lesions ^[21]. Thereby oxidation of the erythrocytes induces oxidative damage to HB, membrane lipids and proteins, which contribute to corpuscular osmotic fragility (COF) and lysis ^[22], also oxidative damage to HB causes changes in its structure and function resulting in denaturation, precipitation and methemoglobin (MetHB) formation in erythrocytes ^[23]. While Malondialdehyde (MDA) is a byproduct of lipid peroxidation (LPO) and its concentration indicated the level of oxidative breakdown of polygenic fatty acids in membranes and an indirect biomarker of free radical generation ^[24], but the formation of protein carbonyls (PCs) is a common phenomenon during oxidation and their quantification indicated the level of oxidative modification of proteins, however oxidized proteins are generally more stable; hence, PCs have a major advantage over LPO products as markers of oxidative damage^[25].

The current study aimed to study transmission of *Theileria annulata* to newborn calves through intrauterine way or not, the pathological changes (Oxidative stress) and reaction of the body (antioxidant) in new born calves.

Materials and methods;

1-Study area;

This study was conducted in crossbreed neonatal calves in some localities in New Valley Governorate (in the western of Egyptian desert). **New Valley Governorate** is one of the governorates of Egypt. It is located in the southwestern part of the country, in Egypt's Western Desert, part of the Sahara Desert – between the Nile, northern Sudan, and southeastern Libya. Consisting of roughly a third of Egypt's area, the New Valley Governorate is the country's largest governorate and one of the biggest on the African continent. The capital is at the Kharga Oasis.

2-Animal;

- a) Twenty crossbreed cows in the last trimester stage of pregnancy, suffering from Theileriosis by clinical signs and laboratory examination were selected and kept under veterinary observation until calving.
- b) Thirty new born calves aged from 1 day to 10 days, classified into two groups. Group A [(20), 18 calves born to the pregnant selected cows aged 1-10 days post-partum where the rest two newborn calves were dead at first day].

Group B [(10), clinical and laboratory healthy new born calves, aged 1-10 days and used as a control healthy calves. The cows and calves were free from tick spp,

3-Samples;

-Blood Samples;

Blood samples were collected from ear vein of selected pregnant cows and new born calves to preparation of three thick and thin smears from each cow to microscopically examine for theileria parasites.

5 ml blood collected from jugular vein of selected pregnant cows and new born calf in clean, labelled and dry sterile tubes containing Ethylene Diamine Tetra-acetic Acid (EDTA) as an anticoagulant to be used for hematological and biochemical analysis in new born calves and DNA extraction in both pregnant cows and its offspring.

4-Clinical examination;

The selected pregnant cows and new born calves were examined clinically according to [1], for the signs of theileriosis and the characteristic clinical signs of new born calves to infected dam consistent with demonstration of the pathogen in circulating erythrocytes and confirmed by PCR analysis must be noticed and recorded.

5- Parasitological examination;

5, 1-Direct smear;

Thin and thick blood smears prepared from selected pregnant cows, its offspring and apparently healthy newborn calves were fixed in absolute methanol for 5 min and stained with 10% Giemsa stain for 30 min. Slides were screened under oil immersion ($\times 100$ magnification) for the presence of intra-erythrocyte periplasms [26, 27]. Animal can be considered negative if the three slides were negative.

5, 2-Quantitative evaluation of parasitemia;

Parasitemia was determined as described by [28], where percentage of infected RBCs was assessed by counting of the number of parasite erythrocytes present per 100 cells at a magnification of $\times 1000$ and expressed as parasitemia percentage. Similarly, the deformed RBC were counted and expressed as echinocytosis percentage.

5, 3-DNA Extraction from Blood;

The DNA was extracted from each sample by chloroform- isoamyl extraction method, all buffers used according to [29]. Blood samples typically were obtained as 1 ml of whole blood stored in EDTA vacutainer tubes. To each 1 ml sample, add 0.8 ml 1X SSC (saline sodium citrate) buffer and mix. Centrifuge for 1 minute at 12,000 rpm in a micro-centrifuge tube, remove 1 ml of the supernatant and discard into disinfectant. Add 1 ml of 1X SSC buffer, vortex, and centrifuge as above for 1 minute and remove all of the supernatant. Add 375 μ l of 0.2M NaOAc (sodium acetate) to each pellet and vortex briefly. Then add 25 μ l of 10% SDS and 5 μ l of proteinase K (20 mg/ml H₂O) (Sigma P-0390), vortex briefly and incubate for 1 hour at 55°C. Add 120 μ l phenol / chloroform/isoamyl alcohol and vortex for 30 seconds. Centrifuge the sample for 2 minutes at 12,000 rpm in a micro-centrifuge tube. Carefully remove the aqueous layer to a new 1.5 ml micro-centrifuge tube, add 1 ml of cold 100% ethanol, mix, and incubate for 15 minutes at -20°C. Centrifuge for 2 minutes at 12,000 rpm in a micro-centrifuge. Decant the supernatant and drain. Add 180 μ l 10:1 TE buffer, vortex, and incubate at 55°C for 10 minutes. Add 20 μ l 2 M sodium acetate and mix. Add 500 μ l of cold 100% ethanol, mix, and centrifuge for 1 minute at 12,000 rpm in a microcentrifuge. Decant the supernatant and rinse the pellet with 1 ml of 80% ethanol. Centrifuge for 1 minute at 12,000 rpm in a micro-centrifuge. Decant the supernatant, and dry the pellet in a Speedy-Vac for 10 minutes (or until dry). Re-suspend the pellet by adding 200 μ l of 10:1 TE buffer. Incubate overnight at 37°C, overtaxing periodically to dissolve the genomic DNA. Store the samples at -20°C

5.3- PCR amplification;

Theileria annulata piroplasm DNA was purified from bovine blood with approximately 25 % parasitemia. Genomic DNA extracted with a Genomic DNA extraction kit (Accu Prep, BIONEER). Aliquots of extracted DNA were kept at 20 °C. PCR was performed using one set of primers (Table 2) (N516GTAACCTTTAAAAACGT 234–250, *T. annulata* specific and N517 GTTACGAACATGGGTTT 954–938, *T. annulata* specific) in a final reaction volume of 100 µl containing 50 mM KCl, 10 mM Tris–HCl (pH 8.3), 1.5 mM MgCl₂, 0.1 % Triton X-100, 200 µM deoxy nucleoside triphosphate, 2.5 U of *Taq* polymerase (Biozyme, England), 20 pmol of primers and 5 µl of template DNA. The reactions were performed in an automatic DNA thermal cycler (Biorad, USA) for 35 cycles. Each cycle consisted of a denaturing step of 1 min at 94 °C, an annealing step of 1 min at 55 °C or 1 min at and an extension step of 1 min at 72 °C. 6.

6 -Hematological analysis;-

5 mL of jugular blood was drawn from each calf in centrifuge tubes containing Na₂EDTA as anticoagulant. Large needles were used in order to minimize the in vitro hemolysis from mechanical injury to erythrocytes. determine erythrocyte count (ER) using a hemocytometer, hemoglobin (HB) concentration and packed cell volume (PCV) were determined by cyan methemoglobin method and hematocrit method respectively [26], Mean corpuscular volume (MCV), Mean corpuscular hemoglobin concentration (MCHC), total leukocyte counts (TLC) on an automatic full digital cell counter (Beckman, USA). Giemsa stained blood smears were used for differential leukocyte counts and detection of periplasm of parasites [30].

7-Biochemical analysis;

7.1- Preparation of erythrocyte membranes (EM);

Immediately after collection of blood samples, centrifuged at 600×g for 15 min at 4 °C. The plasma and buffy coats were removed by aspiration while the sediment containing blood cells was washed three times by re-suspending in isotonic phosphate buffered saline, followed by re-centrifugation and removal of the supernatant fluid and the buffy coats. The crude erythrocytes were lysed with phosphate buffer saline (pH 8.0) and subsequently washed five additional times with the same lysing buffer. EM was collected after each wash by centrifugation at 4 °C for 10 min at 10,000 ×g [31].

7.2; Determination of protein carbonyls (PCs) ;

The DNPH (2,4-dinitrophenylhydrazine) was used for the determination of carbonyl content of proteins in EM as an index of protein oxidation [32]. In Brief, 10 µl of EM was added to 1 ml of 0.2% DNPH, dissolved 20% Trichloroacetic acid was added to each tube to precipitate the protein, after shaking and centrifugation (600xg for 10 min), the supernatant was decanted and 1 ml of ethanol and ethyl acetate (1:1 v/v) solution was added to each tube. The supernatant was decanted and the precipitate was washed with ethanol and ethyl acetate twice. The final pellet was re-dissolved in 1.5 ml of 6 M guanidine hydrochloride and the color of the supernatant was read at 370 nm. The amount of oxidized proteins in the EM was expressed in micromoles PCs/mg proteins.

7.3; Estimation of lipid peroxide (MDA);

Estimation of lipid peroxide (MDA) LPO in erythrocyte membrane was determined by thiobarbituric (TBA) acid reactive substances according to [33], where the idea is depended on forming a color complex between the products of LPO and thiobarbituric acid. Briefly, 0.2 ml of the EM was added to 1.3 ml of 0.2 moles/l Tries, 0.16 moles /l KCl buffer (pH 7.4). TBA (1.5 ml) was added and the mixture was heated in a boiling water bath for 10 min. After cooling, 3 ml of pyridine–butanol (3:1 v/v) and 1 ml of 1 moles/l NaoH were added and the absorbance was read at 548 nm. LPO in the EM was expressed as nmoles of MDA/mg proteins.

7.4; Estimation of Glutathione peroxidase;

The activity of glutathione peroxidase (GSH-Px, µkat/g HB) in heparinized whole blood was assessed by the kinetic method [34], using the sigma Prod. No. G- 3664, kits and using a suitably thermostatic spectrophotometer.

7.5; Estimation of Catalase enzyme;

The activity of catalase enzyme in heparinized whole blood was assessed by kinetic method [35], using the sigma product number C1345, Sigma-Aldrich, kits and using a suitably thermostatic spectrophotometer.

8- Statistical analysis;

Data were expressed as means ± standard error (SE). Differences between groups were determined using an analysis of variance followed by the Student t-test. Pearson's correlation (r) and linear regression analysis (R²) were performed on paired data obtained by individual infected cases. Significance level was set at P < 0.05.

Results;

1-Clinical examination;

Clinical examination were carried on all born calves to be correlated with the result of direct smear and PCR technique, where clinical examination revealed signs, including corneal opacity (Fig 2), temperature, nervous signs, lateral recumbence with edematous mandibular lymph node (Fig 1) and lymphadenopathy in newborn calves positive to direct smear and/or PCR technique (Table 1).

2- Parasitological analysis;

A- Direct smear;

Direct blood smear examination carried on 20 pregnant cows, revealed all the cows harboring *Theileria* parasites with different degree of parasitemia , while direct blood smears examination of new born calves revealed 9 out of 20 (45%) were positive to *Theileria spp* parasites with massive degree of parasitemia, two calves out of 9 positive calf dead during parturition and direct smears of blood and tissues revealed red blood cells bodies of theileria (Table 3,figure 3).

B- PCR amplification;

PCR amplification test carried on selected 20 pregnant cows revealed all selected cows positive to *Theileria parasites* while PCR amplification test carried on 18 from its new born calves indicated 14 out of 20 (including the two dead calves) new born calves (70%) were positive to *Theileria parasites* (Table 3,figure 4).

C- Parasitemia and erythrocyte morphology;

Parasitemia detected in infected cow ranged from 0.5% to 2%. while that in its new borne calf positive to *Theileria parasites* by direct smear, ranged from 1% to 5% Morphologically, almost of erythrocytes of the infected calves lost their normal discoid shape (Fig. 3), deformed and showed the echinocyte form. They looked as wrinkled (crenate) cells with many small sharp, blunt knob-like projections of uniform length, which are evenly distributed around the cell periphery. Echinocytosis was seen in parasite and non-parasite cells of the infected calves. Erythrocytes of the control healthy calves, on the other hand, appeared normal without deformability.

3-Hematological analysis;

Mean values of hematological parameters are presented in Table 4, where in comparison to the control healthy group revealed that significant decrease in TRBCs count, HB content, PCV (%), MCV (fl), MCH (pg/dl) and MCHC (g/dl) and significant increase in TWBCs count in comparison to control healthy calves.

4-Biochemical analysis;

The study paper indicated exposed the infected newborn calves to oxidative stress which evaluated by determination the mean values of MDA (as an index of Lipid peroxidation) and PCs(as a marker of protein oxidation) in EM and the result presented in Table.5, which revealed significantly increased in both parameters by ($P < 0.001$) in comparison to healthy control group, while study the antioxidant parameters revealed no significant change in catalyze enzyme and significant decrease in glutathione enzyme in comparison to healthy control group.

Animal's	Pregnant cows	healthy control calves (group B)	New born calves(group A)	
			Two calves (first day)	18 newborn calves (dead)
Clinical signs				
Temperatures	High temperature (39c-41c).	Normal temperature (39c-39.5c)	39 C	40c-41c in 9 new born calves, rest number with normal temperature
Buccal and vaginal mucus membrane	Pale to icteric mucus membranes	Rosy red mucus membranes	Pale to icteric mucus membranes	9 calves with pale to icteric mucus membranes, rest calves with rosy red membranes
Convulsion (turning sickness)	Absent	Absent	Lateral recumbence	3 born calves present with convulsion signs and lateral recumbence
nasal and ocular discharge	Lacrimation	Absent	Absent	12 born calves with nasal and ocular discharge
Lymphadenopathy.	Enlarged prescupular lymph nodes	Normal size and free moveable lymph nodes	Enlarged prescupular lymph nodes	14 born calves with enlarged prescupular lymph nodes
Opisthosomas	Absent	Absent	Absent	4 born calves with opisthosomas.
Respiration	Shallow, rapid respiration	Normal respiration	Shallow, rapid respiration	6 born calves with shallow rapid respiration
Ticks	Free from ticks	Free from ticks	Free from ticks	Free from ticks

Table 1. Common clinical signs consistent with animals under the study.

Primer	Sequence	Position	Amplified DNA fragment (bp)
N516	GTAACCTTTAAAAACGT	234-250	721
N517	GTTACGAACATGGGTTT	954-938	

Table 2. Oligonucleotide primers used in PCR.

Animals	Pregnant cows			Healthy control newborn calves (Group b)			New born calves for pregnant cows (Group a)		
	NO	Positive	%	NO	Positive	%	NO	Positive	%
Direct smear.	20	20	100%	10	-----	----	20	9	45%
PCR	20	20	100%	10	-----	----	20	14	70%

Table 3. The result of direct smear and PCR in diagnosis of Theileria infection.

Animals	Control calves (n=10)	Infected born calves (n=14)
Parameters		
TRBCS (106 μ L-1)	11.36 \pm 0.61	9.64 \pm 1.56 *
TWBCs (103 μ L-1)	10.64 \pm 0.65	14.86 \pm 2.65 *
HB(g/dl)	12.68 \pm 1.12	7.33 \pm 2.61 *
PCV (%)	31.45 \pm 2.23	21.45 \pm 4.76 *
MCV (fl)	41.12 \pm 1.56	37.17 \pm 8.52 *
MCH(pg/dl)	42.23 \pm 0.35	35.16 \pm 6.21 *
MCHC (g/dl)	45.13 \pm 3.46	38.13 \pm 6.74 *

Table 4; The mean values of hematological parameters in control and infected calves.

Animals	Control healthy (n=10)	infected born calves (n=14)
Parameters.		
Malondialdehyde (MDA)(nmol/mg protein)	146.1 \pm 3.05	189.6 \pm 8.61**
Protein carbonyls (PCs)(μ mol/mg protein)	8.55 \pm 0.41	15.65 \pm 0.67**
Catalase (CAT)(kat/gHB)	31.01 \pm 3.91	31.25 \pm 3.20
Glutathione (GHT)(μ mol/g HB)	4.45 \pm 0.74	3.36 \pm 0.71**

Table 5; The means values of oxidant and antioxidant parameters in control and infected calves.



Figure 1; Lateral recumbence of 4 days calf infected with theileria parasites.

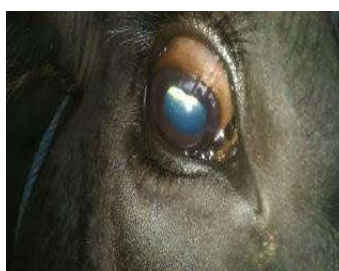

Figure 2; corneal opacity in newborn calf (2 days).

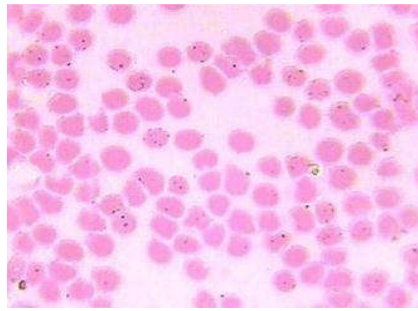


Figure 3; Blood smear stained with giemsa stain showing theileria infected blood cell with echinocytosis.

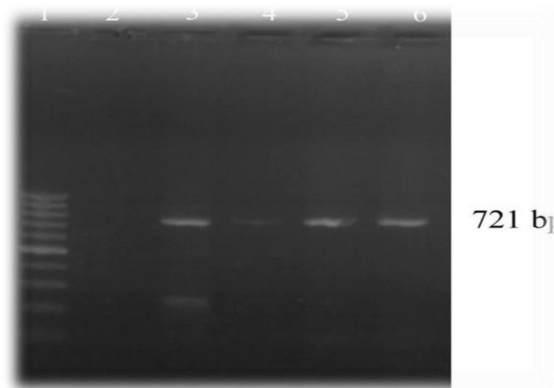


Figure 4; Detection of *Theileria annulata* DNA in newborn calves. The amplified 721-bp product was subjected to electrophoresis in 1.5% agarose gel and stained with ethidium bromide. Lane 1 100-bp ladder. Lane 2 negative control. Lane 3 PCR positive control. Lanes 4,5 and 6 positive samples.

Discussion;

Theileriosis is one of the prevalent protozoans infectious diseases in our country which imposes significant economic losses to dairy industries and already its anemia pathogenesis have been explained. Moreover, free radicals and antioxidants enzymes interactions may play integral roles in different aspects of pathogenesis and finally in a patient destiny [36]. The polymerase chain reaction (PCR) assay is the method used to diagnose theileriosis infection and considered the “gold standard” In our study, where our results demonstrate that this PCR assay detects *T. annulata* parasites at low parasitemia in both 20 infected pregnant cows and 14 out of 18 newborn calves where these findings agree with [37], also agreement with [38, 39], they said that trans-placental transmission of *Theileria spp* has been reported with no known natural exposure to the tick vector in areas where transmitter tick vectors may be present. Thereby our results suggest that subclinical carriers pregnant cow could be serve as a source of infection to new born calves through uterine (Trans-placental transmission). However, recent manifestations documented on trans-placental *Theileria spp* in 1-3 days old cross breed calves were registered which supported that infection of calves by *Theileria spp* in utero can result in neonatal theileriosis [40]. Moreover, [41], added that carrier dams can transmit *Theileria spp* to their offspring and such calves born at term can have a massive parasitemia. The findings have been in continuation with recent reports on trans-placental transmission of *Theileria spp* infection from an immune carrier dam to the fetus [11, 40]. The common clinical signs of the newborn calves include severe ocular discharge, blindness, hyperpnoea, hyper-aesthesia and nervous manifestation. These findings have been agreement with other studies reported by [42, 43] in sporadic cases respectively. Lymphadenopathy, ocular discharge, blindness and nervous manifestation as reported here in seems to be an important documentation of ocular form of congenital Bovine Tropical Theileriosis caused by *Theileria annulata* in a neonate cross bred calf where in normal course trans-steadily transmission of *Theileria. annulata* infected ruminant require an incubation period of 7–21 days after the sporozoites of the pathogen got access into host circulation through the lymph node (s) draining the site of tick bite [1, 44, 45, 27, 46]. Neonate cross bred calves exposed to the infection during gestation period seems exceptions, where the disease in such cases have a shorter incubation period, devoid of enlarged superficial lymph nodes and the affected calves develop clinical signs of the disease much before the normal incubation period, depending upon the pathophysiological involvement of vital organs including CNS and the site of multiplication of the pathogen, consequential extent of damage caused, etc. The signs of the disease appear much before the calf could acquire passive immunity through colostrum from her immune carrier dam [40]. The characteristic clinical signs are in conformity with congenital form of bovine Tropical Theileriosis (BTT) coupled with physical demonstration of the pathogen in the host circulation confirmed that the neonate calf suffered from theileriosis. The nervous signs occurred in the present cases were due to Arthus reaction through the walls of cerebral blood vessels that resulted in vasculitis and lymphocytic inflammation of the brain. These findings are in agreement with other studies in cerebral forms of theileriosis [47].

Hem-gram results indicated a significant decrease in TRBCs, HB, PCV (Table 4), reflect Microcytic hypochromic type of anemia, these results agreement with results recorded by [15, 3, 4, 48]. Where we agreement with [49], in your opinions that the decline in RBCs, PCV and HB may be attributed to the destruction of erythrocytes by macrophages in the lymph

nodes, spleen and other organs of the monocyte macrophage system. Leukogram analysis showed significant increase in total leukocytes count and lymphocytosis in comparison with healthy controls, such changes might be attributed to harmful effects of toxic metabolites of *Theileria* parasites on the haemopoietic organs especially bone marrow and their interference with the process of leukogenesis, However increase in numbers of lymphocytes reflects compensatory mechanism as target cells in response to their invasion with *Theileria* protozoan. [50, 49, 51]. New born calves are especially prone to oxidative stress. The reasons for this are several. New born very often are exposed to high oxygen concentrations, have infections or Inflammation, have reduced antioxidant defense and have high levels of free iron which enhances the Fenton reaction, leading to the production of highly toxic radicals [52]. The elevated MDA observed in the EM in the current work agree with the earlier reports which found increased MDA in the erythrocyte hemolysis of *T. annulata* infected cattle, also the enhanced MDA generation shown in this study reflects increased LPO and points to increased levels of free radical in EM of *Theileria.annulata*-infected calves and agree with previous studies reported also increased amount of LPO by-products (MDA) in erythrocyte hemolysis of adult cattle [53, 36]. However, this paper gives new information about the oxidation of erythrocyte by two criterions including MDA formation for lipids, carbonization of proteins in the cell membrane. The erythrocytes membranes (EM) is rich in polyunsaturated fatty acids, a primary target for reactions involving free radicals, and may allow the erythrocytes vulnerable to oxidative damage [22]. In the erythrocyte, the oxidizing agents enhance oxidative damage to membrane protein principally in the form of disulfidelinked HB-skeletal protein adducts causing HB denaturation and cytoskeletal instability [54]. PCs are not only a good marker for oxidative damage to protein but also a strong oxidizing agent and a causal factor in oxidative injury [25]. Increased erythrocyte membrane PCs in the present study is an indication of the oxidative damage of skeletal membrane protein and provides further evidence of enhanced free radical generation in erythrocytes of newborn calves infected with *T. annulata*. [55].

Oxidative injury to erythrocyte causes loss of fluidity and increased permeability to ions which lead to a decrease in membrane potential, stability and function [23]. In the present study serum Glutathione activity was significantly decreasing (Table 5), in agreement with other studies [3, 8], where glutathione activity is a major mechanism for intracellular decomposition of lipid peroxides and has a crucial role in membranes protection from them, so reduced glutathione is required for the disposal of H₂O₂ from erythrocytes by a reaction catalyzed by glutathione peroxidase, where this reaction is important because accumulation of H₂O₂ might decrease the lifespan of erythrocytes by increasing the rate of oxidation of hemoglobin to methemoglobin [8]. Glutathione enzyme is the principal source of NADPH, which helps in maintaining glutathione in the reduced state, thus protecting erythrocytes from oxidative stress. Glutathione 6 peroxidase (G6PD) serves as an antioxidant enzyme and decreased activity of G6PD has been associated with increased hemolysis in new born calves affected with theileriosis and increased oxidative stress in endothelial cells [36]. Incompatible with our results [53], reported that glutathione activity exhibits a significant rise in cattle naturally infected with *Theileria. Annulata*, but catalase showed no substantial changes.

Conclusion;

Therefore in conclusion, the neonate calf acquired *Theileria annulata* infection from her infected and or immune carrier mother during gestation period, *Theileria anullata* affected newborn crossbred calve develop clinical disease either soon after the birth or during the neonatal life, thereby we seem to considering the trans placental / congenital Bovine Tropical Theileriosis, a fast emerging problem in cross breed cattle population in New-Valley Governorate, Egypt, it would be interesting and most appropriate to precisely investigate the epizootiological determinants, Pathophysiology and immune-pathogenesis of congenital BTT in the affected dams and her off springs while using selective and reliable methodology. This would precisely define financial losses in terms of money, magnitude of the problem and its financial impact on the cattle owners, the diagnosis of the theileriosis with a congenital occurrence was confirmed by evaluation of the calves age, clinical signs, and blood examination as well as demonstration of periplasms and multinuclear schizonts in blood and further studies using PCR to arrive to accurate diagnosis.

Theileris annulata infection in newborn calves is associated with a parasitic burdendependent oxidative damage to the EM protein and lipid contents. This oxidative damage is linked with the morphological changes of the erythrocyte may act as mechanisms contribute to pathogenesis of anemia.

Lipid peroxidation is one of the important consequences of oxidative stress. The intensity of this process can be evaluated by measurement of plasma concentrations of malondialdehyde, as a product of oxidative lipid destruction, increased MDA concentrations after calving indicate imbalance between oxidants and antioxidants, our results showed that systemic oxidative stress exists, which is evidenced by the evaluation of the MDA concentration and no substantial change in CAT due to risk of free radical damage where new calves born are susceptible to the deleterious effects of free radicals, as evidenced by evaluation of MDA concentrations. .

Reference;

- [1]. Radostits, O.M., Blood, D.C. and Gay, C.C ; Veterinary Medicine- A text book of the diseases of Cattle, Sheep, Pigs, Goats and Horses(1994); 8th edn. Bailliere Tindall, London, U.K. pp 1210-1212.
- [2]. Aiello, S.E. and Mays, A(1998); The Merck Veterinary Manual. 8 th ed th. Merck & Co Inc. New. Jersey, USA. 1998. pp 31-33.
- [3]. Nazifi, S., Razavi, S.M., Esmailnejad, Z., Gheisari, H(2009); Study on acute phase proteins (haptoglobin, serum amyloid A, fibrinogen, and ceruloplasmin) changes and their diagnostic values in bovine tropical theileriosis. Parasitol.J. Res. 2009. 105: 41-46. 4-Branco, S., Orvalho, J., Leitão, A., Pereira, I., Malta, M., Mariano, I., Carvalho,

- T., Baptista, R., Shiels, B.R., Peleteiro, M.C (2010); Fatal cases of *Theileria annulata* infection in calves in Portugal associated with neoplastic-like lymphoid cell proliferation. J Vet Sci. 2010.11: 27-34.
- [4]. Razmi, G.R., Barati, F., Aslani, M.R (2009); Prevalence of *Theileria annulata* in dairy cattle in Mashhad area. Iran. J.Vet. Parasitol. 2009. 23: 81-83.
- [5]. Hassanpour, A., Sabegh, Y. G., Sadeghi-nasab, A., (2013) ; Assessment of serum antioxidant enzymes activity in cattle suffering from Theileriosis. Eur. J. Exp. Biol.2013. 3: 493-96.
- [6]. Woods, K. L., Theiler, R., Mühlemann, M., Segiser A, Huber S, Ansari H R, Pain A, Dobbelaere, D. A. E.,(2013) ; Recruitment of EB1, a Master Regulator of Microtubule dynamics, to the Surface of the *Theileria annulata* .Schizont. PLoS. Pathog.2013. 9: 1003346.doi:10.1371/journal.ppat.100334.
- [7]. Razavi, S M, Nazifi, S, Bateni, M, Rakhshandehroo, E.,(2011) ; Veterinary Parasitology, 2011, 180, 209-214.
- [8]. Sharma A, R. and Gxutam, O. P.,(1977) ; Tick-borne Diseases and their Vectors. Indian.
- [9]. Journal of Parasitology, 1977. 1, 87-91.
- [10]. Hubbert, W. T., Rryner, J. H., Folby, J. W., Estes, P. C.,(1975) ; Theriogenology, 1975.3, 43-63.
- [11]. Godara, R., Sharma, R.L., Sharma, C.S.,(2009); Bovine tropical theileriosis in a neonate calf. Trop. Anima. Health. Prod. 2009. 42(4):551–553.
- [12]. Fartashvand, M; Nadalian, M.G; Sakha, M; Safi, S.,(2013); Elevated serum cardiac troponin in cattle with Theileriosis. J Vet Intern Med 27: 2013.194-199.
- [13]. Singh SK, Sudan V, Sachan P, Srivastava A.,(2013); Salvage of *Theileria* infected calves with clinical manifestation of exophthalmia. J .Parasit. Dis. 2013 Doi .10 .1007 /s 12639-0130364-8.
- [14]. Chandra. K; Syed S. A., Abid Mohd., Sweetey R., Najam A. k.,(2015); "Protection against FCA Induced Oxidative Stress Induced DNA Damage as a Model of Arthritis and In vitro Anti-arthritis Potential of *Costus speciosus* Rhizome Extract". International Journal of Pharmacognosy and Phytochemical Research .2015. 7 (2): 383–389.
- [15]. Forsyth, L.M., Minns, F.C., Kirvar, E., Adamson, R.E., Hall, F.R., Mcorist, S., Brown,
- [16]. C.G., Preston, P.M.,(1999); Tissue damage in cattle infected with *Theileria annulata* accompanied by metastasis of cytokine-producing schizont-infected mononuclear phagocytes. J. Comp. Pathol. 1999.120, 39–57.
- [17]. Ahmed, J.S., Glass, E.J., Salih, D.A., Seitzer, U., (2008); Review innate immunity to tropical theileriosis. Innate Immun.j. 2008 (14), 5–12.
- [18]. Shiono, H., Yagi, Y., Chikayama, Y., Miyazaki, S., Nakamura, I.,(2003); The Influence of oxidative bursts of phagocytes on red blood cell oxidation in anemic cattle infected with *Theileria sergenti*. Free Radic. Res. 2003. 37, 1181–1189.
- [19]. Turrens, J.F., (2004); Oxidative stress and antioxidant defenses: a target for the treatment of diseases caused by parasitic protozoa. Mol. Aspects Med. J.2004. 25, 211–220. 19- Comporti, M., Signorini, C., Buonocore, G., Ciccoli, L.,(2002); Iron release, oxidative stress and erythrocyte ageing. Free Radica. Biol. Med. 2002.32,568–576.
- [20]. Gaal, T., Ribiczeyne-Szabo, P., Stadler, K., Jakus, J., Reiczigel, J., Kover, P., Mezes, M., Sumeghy, L.,(2006); Free radicals, lipid peroxidation and the antioxidant system in the blood of cows and newborn calves around calving. Comp. Biochem. Physiol. B. 2006.143, 391– 396.
- [21]. Valko, M., Leibfritz, D., Moncol, J., Cronin, M.T.D., Mazur, M., Telser, J., (2007); Free radicals and antioxidants in normal physiological functions and human disease. Int. J.
- [22]. Biochem. Cell Biol. 2007. 39, 44–84.
- [23]. Harvey, J.W., (2008); The erythrocyte: physiology metabolism and biochemical disorders. In: Kaneko, J.J., Harvey, J.W., Bruss, M.L. (Eds.), Clinical biochemistry of domestic animals, sixth ed. Academic Press, London, 2008.pp. 173–240.
- [24]. Kanas, T., Acker, J.P., (2010); Bio-preservation of red blood cells the struggle with hemoglobin oxidation. FEBS J. 2010. 277, 343–356.
- [25]. Cimen, M. Y.,(2008); free radical metabolism in human erythrocytes. Clin. Chem Acta. J, 2008. 390, 1-11.
- [26]. Dalle-Donne, I., Aldini, G., Carini, M., Colombo, R., Rossi, R., Milzani, A., (2006); Protein carbonization, cellular dysfunction, and disease progression. J. Cell. Mol. Med.2006. 10, 389–406.
- [27]. Coles, E.H.,(1980); Veterinary Clinical Pathology, 3 rd. edition .Saunders Philadelphia .pp. 1980. 75- 90.
- [28]. Taylor, M.A., Coop, R.L., Wall, R.L.,(2007); Veterinary Parasitology. 3rd edth. Blackwell Publishing Ltd, UK. 2007. pp 109-113.
- [29]. Conrad, P.A., Kjemtrup, A.M., Carreno, R.A., Thomford, J., Wainwright, K., Eberhard, M., Quick, R., Telford, S.R., Herwaldt, B.L., (2006) ;Description of *Babesia duncanin.sp.* (Apicomplexa: babesiidae), from humans and its differentiation from other piroplasms. Int. J. Parasitol. 2006. 36, 779–789.
- [30]. Sambrook J.; Fritsch, E.F. and Maniatis T., (1989); Molecular Cloning: a Laboratory Manual. Cold spring . Harbor Laboratory Press, New York .1989.
- [31]. Weiss, D.J., Wardrop, K. J. Schalm's.,(2010) ; Veterinary Hematology, 6 editions. 2010. (Ames, Wiley-182 Blackwell).
- [32]. Dodge, J.T., Mitchell, C., Hanahan, D.J.,(1963); the preparation and chemical characteristics of hemoglobin-free ghosts of human erythrocytes. Arch . Biochem. Biophys. 1963. 100, 119–130.
- [33]. Stadtman, E.R., Levine, R. L., (2003) ; Free radical-mediated oxidation of free amino acids and amino acid residues in proteins. Amino. Acids.J. 2003. 25, 207–218. 33-Placer, Z.A., Cushman, L.L., Johnson, B.C.,(1966) ; Estimation of product of Lipid peroxidation (malonyldialdehyde) in biochemical systems. Anal. Biochem.J. 1966.16, 359– 364.
- [34]. Wendel, A.,(1980) ; Enzymatic Basis of Detox cation, 1980. Volume.1. pp. 333, Academic. Press, N.Y.

- [35]. Li, Y and Schellhorn, H. E.,(2007) ; Rapid kinetic micro assay for catalase activity. J. Biomol. Tech.2007.18, 185–187.
- [36]. Rezaei, A. S and Dalir-Naghaded, B.,(2006) ; Evaluation of antioxidant status and oxidative stress in cattle infected with *Theileria annulata*. Veterinary Parasitology, 2006.142, 179-186.
- [37]. Stoltz, W .H.,(1989) ; Theileriosis in South Africa: A brief review. Rev Sci Tech. 1989.8(1): 93-102.
- [38]. Mishra, A. K., Sharma, N. N., Srivastava, S. C.,(1994);*Theileria annulata* infection in neonatal bovine calves. Acta. Vet. Hung.1994. 42 (1) 99-102.
- [39]. Issi, M and Gul, Y.,(2008) ; Tropical theileriosis in newborn two calves. Yüzüncü yıl Üniversitesi .Veterinary .Fakültesi . Dergisi.2008. 19 (2) 67-69.
- [40]. Sudan V; Sharma, R. L; Borah, M. K; Mishra, R.,(2012); Acute bilateral proptosis in a cross bred calf naturally infected with *Theileria annulata* .J. Parasite. Dis (July-Dec 2012) 36(2):215–219.
- [41]. Onoe, S.,Sugimoto, C.,Tanaka, M.,Kubota, S., Hirai, T.,Yonemichi, H.,Mori, K ., Onuma, M.,(1994) ; Prenatal infection with *Theileria sergenti* in calves . J. Protozool . Res.1994. 4 (3) 119-123.
- [42]. Saville, W.J.A., (2002); cerebral theileriosis. In: Smith BP (Eds.).Large animal internal medicine. 3rd ed. St. Louis, USA: Mosby; 2002.917 -918.
- [43]. Dabak, M; Aktas, M and Dabak, D. O.,(2004) ; Cerebral theileriosis in a Holstein calf. Vet Rec.J.2004; 154(17): 533-534.
- [44]. Urquhart, G. M, Armour, J; Duncan, J.L; Dunn, A. M, Jennings, F.W.,(2003) ; Veterinary parasitology. Blackwell Science Ltd., UK, 2003. pp 246–249.
- [45]. Soulsby, E. J.L.,(2005) ; Helminths, arthropods and protozoa of domesticated animals, ELBS-7. Bailliere Tindal, London, 2005. pp 728–737.
- [46]. Lefevre, P.S; Blancou, J; Chermette, R; Uilenberg, G.,(2010) ; Infectious and parasitic diseases of livestock. Lavoisier Tec & Doc.2010.,pp 1839–1866.
- [47]. Mohammad,T. K ., Javad, A. H, Ezzat, O.F.,(2014) ; Occurrence of congenital cerebral theileriosis in a newborn twin Holstein calves in Iran: Case report. V.R. Forum. 5 (3) 2014. 237 – 241.
- [48]. Khan, I.A., Khan, A., Hussain, A., Riaz, A., Aziz, A.,(2011) ; Hemato-Biochemical Alterations in Cross Bred Cattle Affected with Bovine Theileriosis in Semi-Arid Zone. Pak .Vet .J. 2011.31(2): 137-140.
- [49]. Singh A., Singh, J., Grewal, A S., Brar, R S.,(2001); Studies on some blood parameters of cross bred calves with experimental *Theileria annulata* infections. Vet. Res. Comm. 2001. 25, 289–300.
- [50]. Omuse, J. K.,(1987); A comparative hematological picture of field cases of East coast fever, Anaplasmosis and Babesiosis in bovine around Kabete. In: "Tick born disease and their vector"1st ed by Wild J.K, Center for tropical veterinary medicine. University of Edinburgh. 1987. PP: 181-187.
- [51]. Morrison, W. I.,(2004) ; *Theileria annulata*: Kinetics of infection in lymphoid system of cattle. Exper. Parasitol. 2004. 52(2): 248-260.
- [52]. Gitto, E.,Pellergrino, S.,Gitto, P.,Barber, I.,Reiter, R.,(2009) ;Oxidative stress of the newborn in the pre- and postnatal period and the clinical utility of melatonin. J. Pineal .Res.46, pp. 2009.128-139.
- [53]. Grewal, A., Ahuja, C.S., Singha, S.P.S., Chaudhary, K.C.,(2005); Status of lipid Peroxidation, some antioxidant enzymes and erythrocyte fragility of crossbred cattle naturally infected with *Theileria annulata*. Vet. Res. Commun . 2005.29, 387–394.
- [54]. McMillan, D.C., Powell, C.L., Bowman, Z.S., Morrow, J.D., Jollow, D. J.,(2005) ; Lipids versus proteins as major targets of pro-oxidant, direct-acting hemolytic agents. Toxicol. Sci.J.2005. 88, 274–283
- [55]. Yagi, Y., Thongnoon, P., Shiono, H., Chikayama, Y., (2002); Increase in oxidized proteins in *Theileria sergenti* infected erythrocyte membrane. J. Vet. Med. Sci. 2002. 64, 623–625.